


PRESENTING CLINICAL SIGNS

History: Previously diagnosed with degenerative valve disease. Coughing/gagging. Receiving pimobendan 5 mg BID.

DATE

3/7/23

ECHOCARDIOGRAPHIC FINDINGS

2D, M-mode, and Doppler study.

PERFORMED BY:

Shari Reffi, CVT

INTERPRETED BY

 Keith Blass, DVM,
 MS, DACVIM
 (Cardiology)

There is mild left atrial dilation. The mitral valve leaflets are thickened and exhibit systolic prolapse. There is Doppler evidence of mitral regurgitation present. Left ventricular dimensions are normal. Left ventricular systolic function is hyperdynamic. The aorta and aortic valve appear normal, though there is mildly increased flow velocity in the ascending aorta. Right atrial and right ventricular dimensions are normal. The tricuspid valve appears normal, though trace tricuspid regurgitation is present. The pulmonary artery and pulmonary are normal. No shunting lesions are visualized. No pericardial effusion or cardiac masses are seen.

PATIENT

Cookie Nelson

LA - 38.8 mm
 LA/Ao - 1.50
 LVIDd - 36.0 mm
 LVIDs - 18.8 mm
 FS - 47.8%
 RA - 23.6 mm
 LVOT - 2.34 m/s
 RVOT - 0.95 m/s

SPECIES

Canine

ASSESSMENT/RECOMMENDATIONS

Degenerative mitral valve disease

BREED

Beagle

This examination demonstrates regurgitation of blood across Cookie's mitral valve resulting from her previously diagnosed degenerative valve disease. Secondary to her regurgitation, Cookie has mild dilation of her left atrium, though her left ventricular dimensions are normal, and her left ventricular systolic function is well-preserved. As only mild left atrial dilation is present, it's unlikely that Cookie's cough/gag is cardiogenic in origin, and thoracic radiographs are recommended for further evaluation. Cookie's current risk for the development of exercise intolerance, syncope, and labored breathing, appears to be relatively low, though careful monitoring for these signs is still recommended.

SEX

FS

No change in therapy is recommended based on this exam. Therapy for Cookie's cough/gag should ideally be based on the results of thoracic radiography.

AGE

6 y

A recheck echocardiogram is recommended in 9 months. Repeat radiographs are recommended if Cookie experiences labored breathing.

WEIGHT

39 lb

HOSPITAL NAME

Milford AH

REFERRING VET

Dr. Grasso



DATE

3/7/23

PERFORMED BY:

Shari Reffi, CVT

INTERPRETED BY

Keith Blass, DVM,
MS, DACVIM
(Cardiology)

PATIENT

Cookie Nelson

SPECIES

Canine

BREED

Beagle

SEX

Keith Blass, DVM, MS, DACVIM (Cardiology)
KeithBlass@gmail.com
631-804-5754

AGE

6 y

WEIGHT

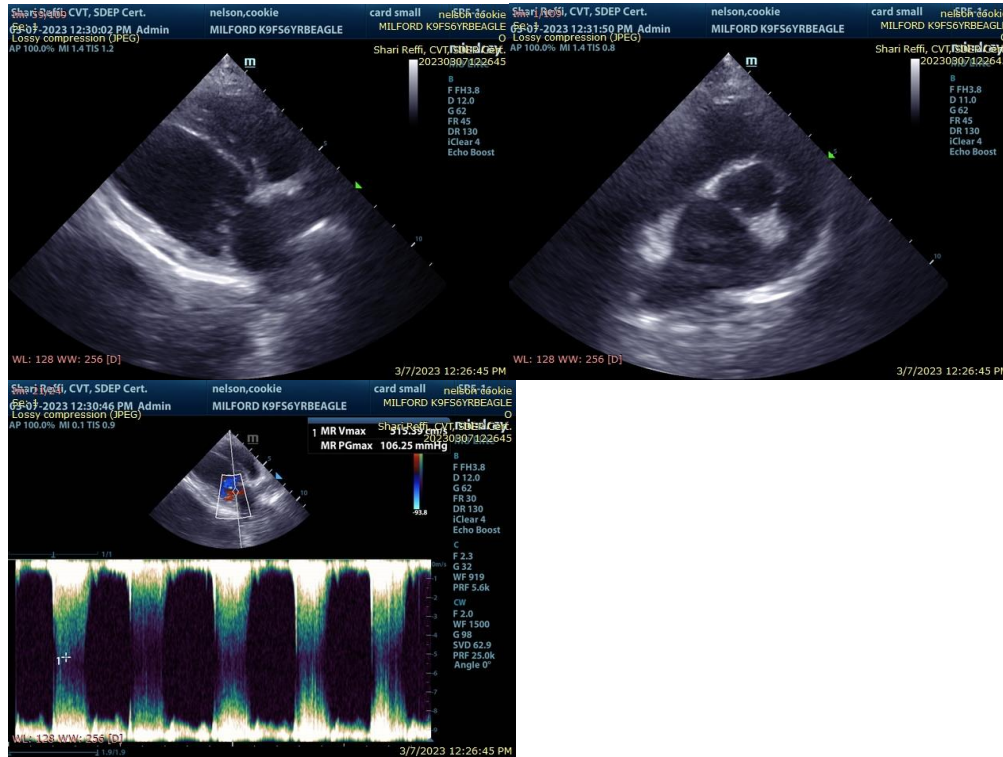
39 lb

HOSPITAL NAME

Milford AH

REFERRING VET

Dr. Grasso



The information and recommendations provided are based on the images presented by the referring veterinarian. No evaluation can be communicated regarding pathology that was not visible in the image/video clips provided.

Thank you for this referral. If the clinical or image interpretation does not parallel your findings or if I can be of any further assistance please contact me.